

AIC Guidelines in Restorative Dentistry

*Accademia Italiana di Conservativa
Italian Academy of Restorative Dentistry*

Draft Nr.10

Introduction

The present chapter is dealing with operative parameters of restorative dentistry.

Definition of Restorative Dentistry.

Restorative (or Conservative) Dentistry is the branch of dentistry that deals with the prevention and treatment of both congenital and acquired lesions to the calcified tissues of teeth.

Purposes of restorative therapy.

The restorative therapy aims to achieve the following objectives:

- Elimination of the causes of the disease and patient's motivation to optimal control of bacterial plaque and to follow a proper diet.
- Interception and if possible arrest of initial decalcifying lesions through non-invasive therapies and remineralization
- Prevention of caries lesions by non-invasive but irreversible measures (fissure sealing)
- Conventional therapy of hard tissues lesions with the following objectives:
 - a) maintenance of pulp vitality and prevention of future damage to calcified tissues;
 - b) restoration of form and function of the single teeth;
 - c) aesthetic integration of the restoration at normal distance of conversation, if this is what is desired by the patient and clinically feasible.

Preliminary considerations.

Restorative dentistry not accompanied by careful prophylactic measures will solve only temporarily the problems of the patient: the carious lesions will likely return to occur.

It is therefore recommended that the restorative procedures are accompanied and followed by individual prophylactic measures.

The restorative treatment must be performed in due time, following a treatment plan that identifies and connects the patient's problems and is not solely focused on the treatment of the carious lesions¹.

The specifically restorative treatment plan, inserted into a global dental treatment plan, should therefore include:

- determination of the patient's caries risk.

The determination of the risk of caries (high, low, average) can direct us to an operating procedure rather than another, or can make us opting for different materials.

It's also useful to determine the type and frequency of prophylactic measures to be prescribed to the patient both at home and in the dental office.

In this phase the excavation and the temporary filling of the coarser carious lesions can already be indicated, in order to reduce the bacterial load;

- determination of the patient's expectations and its willingness to deal with dental treatment.

Some patients consider with great importance the health and aesthetics of the oral cavity; others tend only to seek emergency treatment, others present with a middle demand between these instances.

The evaluation of the patient in this regard can provide us with valuable tips to predict his future level of cooperation during and after treatment (oral hygiene and regular control visits).

- the diagnosis of all carious lesions present, and if possible determination of their level of activity.

A correct diagnosis is not possible without a thorough physical examination, the execution of bitewing (and periapical) Rx when indicated, and pulp sensitivity testing.

- determination of both soft and hard periodontal tissues condition in relation with the restorative treatment.

- determination of the situation of occlusion.

Occlusal disorders that may be present may influence the choice of materials and techniques to be used.

- treatment plan.

The treatment plan must be explained to the patient.

1-Benn DK, Clark TD, Dankel DD 2nd, Kostewicz SH: Practical approach to evidence-based management of caries. J Am Coll Dent 1999 Spring;66(1):27-35.

OPERATIVE RECOMMENDATIONS

Caries prevention.

Dental caries is a disease that can be largely prevented^{2,3,4,5,14,15,16,17}.

A good caries prevention program includes sessions of oral hygiene and control visits, application of fluoride both professional and at home (mouthwashes, toothpastes etc.), instructions for a good plaque control at home, including the interdental hygiene, and dietetic suggestions^{6,7,8,10,11,12,13}.

In childhood subjects the systemical fluoride intake represents an excellent protection factor^{6,10,15}.

Patients with root surface exposures (gingival recessions, elderly patients...) are at increased risk of root caries⁹. These patients should be motivated to effective oral hygiene procedures and to the self-application of fluoride⁹.

An increased risk of caries is also present in patients taking specific medications¹² or whose salivary flow, for several reasons- is reduced^{13,17}.

2-Fejerskov O: Strategies in the design of preventive programs. Adv in Dent Res 1995;9:82-88.

3-Hausen H: Caries prediction-state of the art. Comm Dent & Oral Epidem 1997;25:87-96.

4-Powell LV: Caries risk assessment: relevance to the practitioner. JADA 1998;129(3):349-353.

5-Pitts NB: Risk assesement and caries prediction. J Dent Educ 1998;62:762-770.

6-Triller M: Fluoride, a preventive agent of caries: mechanisms, sources, risks. Archive de Pediatrie 1998;5:1149-1152.

7-Anusavice KJ: Management of dental caries as a chronic infectious disease. J of Dent Educ 1998;62:791-802

8-Caufield PW: Dental caries - a transmissible and infectious disease revisited: a position paper. Pediatric dent 1997;19:491-498. I

9-Zambon JJ, Kasprzak SA: The microbiology and histopathology of human root caries. Am J of Dent 1995;8:323-328.

10-Mandel ID: Caries prevention: current strategies, new directions. JADA 1996;127:1477-1488.

11-Van Palenstein Helderma WH, Matee MI, van der Hoeven JS, Mikx FH: Cariogenicity depends more on diet than the prevailing mutans streptococcal species. J Dent Res 1996;75:535-545.

12-Ciancio SG: Medications as a risk factor for caries and periodontal disease. NYS Dent J 1997;59:962-971.

13-Edgar WM, Higham SM: Role of saliva in caries models. Adv in Dent Res 1995;9:235-245.

14-Radnai M, Fazekas A: Caries prevalence in adults seven years after previous exposure to fluoride in domestic salt. Acta Med dent Helv 1999;4:163-166.

15-Steiner M, Menghini G, Curilovic Z, Marthaler TM: Kariesprävalenz bei Zürcher Schulkindern 1970, 1983 and 1988. Schweiz Monatsschr Zahnmed 1990;100:38-41.

16-Elderton RJ: Assessment and clinical management of early caries in young adults: invasive versus non-invasive methods. Br Dent J 1985;158:440-444. I

17-König KJ: Remineralization, Firmenpublikation Elida Cosmetic Ag 1984, ISBN Schweiz 3 9055 2901 7.

Diagnosi

A correct diagnosis must obviously precede every type of therapy^{18,19,20,21,22}. In general the exploring alone should be resized as a diagnostic value^{23,24,25,26,27,28,29}. A good visual inspection with teeth thoroughly dry and free from deposits and pigmentation is probably able to offer the most valuable information, together with bitewing radiographs when indicated^{30,31,32,33,34,35,36,37,38,39,40,41,42,43}.

Recommendations

- *Dental caries can be largely prevented; prevention programs should therefore precede, accompany and follow the restorative treatment; **Lev.I***
- *A correct diagnosis of caries and the determination of the pulp sensitivity must precede any therapeutic procedure; **Lev.II***
- *The bitewing radiographs can be an important aid in the diagnosis of interproximal carious lesions; **Lev.I***
- *Any periodontal and occlusal problems should be evaluated before embarking on any type of restorative therapy. **Lev.II***

18-Tveit AB, Espelid I, Fjelltvait A: Clinical diagnosis of occlusal dentine caries. Caries Res 1994;28:368-372.

- 19-Silverstone LM, Hicks MJ, Featherstone MJ: Dynamic factors affecting lesion initiation and progression in human dental enamel. Part I. The dynamic nature of enamel caries. Quintessence International 1988;10:683-711.
- 20-Lussi A: Methoden zur Diagnose und Verlaufsdiagnose der Karies. Schweiz Monatsschr Zahnmed 1998;108:357-363.
- 21-Stecksen-Blicks C, Wahlin YB: Diagnosis of approximal caries in pre-school children. Swed Dent J 1983;7(5):179-84.
- 22-Edward S: Changes in caries diagnostic criteria over time related to the insertion of fillings. A comparative study. Acta Odontol Scand 1997 Jan;55(1):23-6.
- 23-Ie YL, Verdonchot EH, Schaeken MJM, van't Hof MA: Electrical conductance of fissure enamel in recently erupted molar teeth as related to caries status. Caries Res 1995;29:94-99.
- 24-Ricketts D, Kidd E, Wilson R: The electronical diagnosis of caries in pits and fissures: site-specific stable conductance readings or cumulative resistance readings? Caries Res 1997;31:119-124.
- 25-Machiulskiene V, Nyvad B, Baelum V: A comparison of clinical and radiographic caries diagnoses in posterior teeth of 12-year-old Lithuanian children. Caries Res 1999 Sep-Oct;33(5):340-8.
- 26-Weerheijm KL, Groen HJ, Bast AJ, Kieft JA, Eijkman MA, van Amerongen WE: Clinically undetected occlusal dentine caries: a radiographic comparison. Caries Res 1992;26(4):305-9.
- 27-Hintze H, Wenzel A: Clinically undetected dental caries assessed by bitewing screening in children with little caries experience. Dentomaxillofac Radiol 1994 Feb;23(1):19-23.
- 28-Ricketts DN, Kidd EA, Smith BG, Wilson RF: Clinical and radiographic diagnosis of occlusal caries: a study in vitro. J Oral Rehabil 1995 Jan;22(1):15-20.
- 29-Huysmans MC, Longbottom C, Pitts N: Electrical methods in occlusal caries diagnosis: An in vitro comparison with visual inspection and bite-wing radiography. Caries Res 1998;32(5):324-9.
- 30-Weiss EI, Tzoar A, Kaffe I: Interpretation of bitewing radiographs. Part 2. Evaluation of the size of approximal lesions and need for treatment. J Dent 1996;24:385-388.
- 31-Zacharia MA, Munshi AK: Microbiological assessment of dentin stained with a caries detector dye. J Clin Pediatr Dent 1995;19:111-115.

- 32-Verdonschot EH, Kuijpers JMC, Polder BJ, DE Leng-Worm MH, Bronkhorst EM. Effects of digital grey - scale modification on the diagnosis of small approximal carious lesion. J Dent 1992;20:44-49.
- 33-Pitts NB, Kidd EAM: The prescription and timing of bitewing radiography in the diagnosis and management of dental caries: contemporary recommendations. British Dental Journal 1992;21:225-227.
- 34-Pitts N: Monitoring of caries progression in permanent posterior approximal enamel by bitewing radiography: a review. Community Dent Oral Epidemiol 1983;11:228-235.
- 35-Curilovic Z, Saxer UP; Marthaler TM: Radiologische Kariesläsion im Schmelz - füllen oder abwarten? Schweiz Monatsschr Zahnmed 1983;93:930-934.
- 36-Hintze H: Screening with conventional and digital bite-wing radiography compared to clinical examination alone for caries detection in low-risk children. Caries Res 1993;27(6):499-504.
- 37-Verdonschot EH, van de Rijke JW, Brouwer W, ten Bosch JJ, Truin GJ: Optical quantitation and radiographic diagnosis of incipient approximal caries lesions. Caries Res 1991;25(5):359-64.
- 38-de Vries HC, Ruiken HM, Konig KG, van 't Hof MA: Radiographic versus clinical diagnosis of approximal carious lesions. Caries Res 1990;24(5):364-70.
- 39-De Araujo FB, Rosito DB, Toigo E, dos Santos CK: Diagnosis of approximal caries: radiographic versus clinical examination using tooth separation. Am J Dent 1992 Oct;5(5):245-8.
- 40-Hintze H, Wenzel A, Danielsen B: Behaviour of approximal carious lesions assessed by clinical examination after tooth separation and radiography: a 2.5-year longitudinal study in young adults. Caries Res 1999 Nov-Dec;33(6):415-22.
- 41-Nyvad B, Machiulskiene V, Baelum V: Reliability of a new caries diagnostic system differentiating between active and inactive caries lesions. Caries Res 1999 Jul-Aug;33(4):252-60.
- 42-Mejare I, Kallestal C, Stenlund H, Johansson H: Caries development from 11 to 22 years of age: a prospective radiographic study. Prevalence and distribution. Caries Res 1998;32(1):10-6.
- 43-Downer MC, Worthington HV: The status of bite-wing radiographs in enhancing discriminatory ability in caries prophylactic clinical trials. Caries Res 1992;26(3):195-200.

Operative field isolation.

All restorative materials, coatings, luting and adhesives are moisture sensitive^{44,45,46,47,48}. The effective isolation of the operative field also reduces the bacterial contamination of dentin^{49,50,51,52,53,54}.

44-Reid JS, Callis PD, Patterson CJW: Rubber Dam in Clinical Practice. Chicago, Quintessence Publ Co,1990, pp 5-20.

45-Hitmi L, Attal JP, Degrange M: Influence of the time-point of salivary contamination on dentin shear bond strength of 3 dentin adhesive systems. J Adhes Dent 1999;1(3):219-32.

46-Strassler HE: Isolation of the field more important than ever. MSDA J 1996 Fall;39(3):119-21.

47-Lygidakis NA, Oulis KI, Christodoulidis A: Evaluation of fissure sealants retention following four different isolation and surface preparation techniques: four years clinical trial. J Clin Pediatr Dent 1994 Fall;19(1):23-5.

48-Small BW: Seating, finishing, and polishing of ceramic restorations. Gen Dent 1999 Nov-Dec;47(6):560-2. I

49-Zitzmann NU, Elsasser S, Fried R, Marinello CP: Foreign body ingestion and aspiration. Oral Surg Oral Med Oral Pathol Oral Radiol Endod 1999 Dec;88(6):657-60. I

50-Kremers L, Halbach S, Willruth H, Mehl A, Welzl G, Wack FX, Hickel R, Greim H: Effect of rubber dam on mercury exposure during amalgam removal. Eur J Oral Sci 1999 Jun;107(3):202-7.

51-Small BW: Rubber dam-the easy way. Gen Dent 1999 Jan-Feb;47(1):30-3.

52-Berglund A, Molin M: Mercury levels in plasma and urine after removal of all amalgam restorations: the effect of using rubber dams. Dent Mater 1997 Sep;13(5):297-304.

53-Marshall K : Rubber dam. Br Dent J 1998 Mar 14;184(5):218-9.

Plasmans PJ, Creugers NH, Hermesen RJ, Vrijhoef MM: Intraoral humidity during operative procedures. J Dent 1994 Apr;22(2):89-91.

54-Christensen GJ: Using rubber dams to boost quality, quantity of restorative services. J Am Dent Assoc 1994 Jan;125(1):81-2.

Cavity preparation.

The first and fundamental concept is the highest limitation of the cavity extension; healthy mineralized dental tissues must be preserved as much as possible, compatibly with the techniques and the materials chosen for the restoration^{55,56,57,58,59,60}.

The cavity dimensions are directly proportional to the importance of the carious process ^{61,62,63,64,65}.

For a safer control of the rotating instruments, it is recommended that the use of the air-driven hanpiece is limited to the first steps of cavity opening and preparation ^{64,66}. It is instead advisable to perform the final shaping of the cavity and the finishing of the margins with medium and / or low speed handpieces. ^{67,68,69}.

All of these steps must be performed under copious water spray to avoid injury to the pulp-dentin complex ^{55,61,64,66}.

A smooth cavity margin without fractures greatly influences the marginal fit of the restoration, and therefore its durability ^{70,71,72,73,74}. For this reason it is necessary to finish the margins with appropriate instruments ^{70,74}.

Recommendations

- *The preparation of the cavity must be the more conservative possible, consistent with the techniques and the materials chosen for the restoration; **Lev.II***
- *The proper margin finishing is recommended as this improves marginal adaptation and influences the durability of the restoration; **Lev.II***
- *A proper isolation of the operating field is essential for therapeutic success. **Lev. II***

SCHEME

Cavity preparation: steps.

- 1 - cavity opening - access to the lesion
- 2 - caries excavation
- 3 - evaluation of the cavity dimensions
- 4 - final cavity preparation
- 5 - finishing of margins

55-Hirt T Lutz F: Conservative Amalgam Restoration. Schweiz Monatsschr Zahnmed 1987;97:1261-1270.

56-Loe H: Changing paradigms in restorative dentistry. J Am Coll Dent 1995;3:31-36.

57-Leinfelder KF: A conservative approach to placing posterior composite resin restorations. JADA 1996;6:743-748.

58-Simonsen RJ: Conservation of tooth structure in restorative dentistry. Quintessence Int 1985;16:15-24.

59-Osborne JW, Summitt JB: Extension for prevention: is it relevant today? Am J Dent 1998 Aug;11(4):189-96.

60-Miller MB: Rest in peace G.V. Black: part I. Pract Periodont Aesthet Dent 1997;7:757-758.

61-Anusavice KJ: Material of the future: preservative or restorative? Operative Dentistry 1998;23:163-167.

62-Elderton RJ: Assessment and clinical management of early caries in young adults: invasive versus non-invasive methods. Br Dent J 1985;158:440-444.

- 63-Christensen GJ: Cavity preparation: cutting or abrasion? JADA 1996;127:1651-1654.
- 64-Laswell HR, Welk DA: Rationale for designing cavity preparations. Dent Clin North Am 1985;2:241-249.
- 65-Freedman G, Goldstep F, Seif T, Pakroo J: Ultraconservative resin restorations. J Can Dent Assoc 1999 Nov;65(10):579-81. I
- 66-Porte A, Lutz F, Lund M R, Swartz M L & Cochran M A: Cavity designs for composite resins. Oper Dent 1984;9:50-56.
- 67-Moopnar M, Faulkner KDB: Accidental damage to teeth adjacent to crown-prepared abutment teeth. Austral Dent J 1991;36:136-140.
- 68-Medeiros VA, Seddon RP: Iatrogenic damage to approximal surfaces in contact with Class II restorations. J Dent 2000 Feb;28(2):103-10.
- 69-Lussi A, Gygax M: Iatrogenic damage to adjacent teeth during classical approximal box preparation. J Dent 1998 Jul-Aug;26(5-6):435-41.
- 70-Haller B, Klaiber B, Tens KD: Einfluss der Kavitätenfinierung auf das initiale Abdichtungsvermögen von Amalgamfüllungen in vitro. Schweiz Monatsschr Zahnmed 1991;101: 986-992.
- 71-Kidd E A M, Toffenetti F, Mjör I A: Secondary caries. Int Dent J 1992;42:127-138.
- 72-Nordbo H, Leirskar J, von der Fehr FR: Saucer-shaped cavity preparations for posterior approximal resin composite restorations: observations up to 10 years. Quintessence Int 1998 Jan;29(1):5-11. I
- 73-Stratis S, Bryant RW: The influence of modified cavity design and finishing techniques on the clinical performance of amalgam restorations: a 2-year clinical study. J Oral Rehabil 1998 Apr;25(4):269-78.
- 74-Reller U, Geiger F, Lutz F: Quantitative investigation of different finishing methods in conventional cavity preparations. Quintessence Int 1989;20:453-459.

Direct or indirect restorations?

The decision whether to perform direct or indirect restorations depends on many factors ^{75,77,79}.

The size of the carious process is an important factor of choice ⁷⁷.

In general, an indirect restoration (inlay) can be more invasive than a direct restoration (filling) ^{76,77,78,79}.

Therefore, in the treatment of carious lesions of limited size, the execution of direct restorations is probably preferable ^{75,77}.

Likewise, in patients at high risk for caries and in young patients is probably preferable to resort to direct fillings ^{75,77}.

SCHEME

Decision between direct or indirect restoration: factors to be considered

Clinical factors:

Extension of the carious lesion

Presence or absence of enamel at the cervical cavity wall

Configuration and complexity of the cavity

Localisation and access

Number of restorations in the same arch

Relationships with approximal and opposing teeth

Patient's age

Caries risk

Subjective patient's factors:

Acceptance of the need of a temporary restoration

More or less important aesthetic demands

Problems of time and distance

Financial availability

75-Krejci I: Standortbestimmung in der Konservierenden Zahnmedizin. Schweiz Monatsschr Zahnmed 1993;103:614-619.

76-Anusavice KJ: Criteria for selection of restorative materials: properties versus technique sensitivity, in Anusavice KJ (ed): Quality Evaluation of Dental

Restorations: Criteria for Placement and Replacement. Chicago, Quintessence Publ Co, 1989, pp15-59.

77-Surmont P, Martens L, D'Hauwers R: A decision tree for the treatment of caries in posterior teeth. Quintessence Int 1990;21:239-246.

78-Mjör I A: Direct posterior filling materials. In Vanherle G, Degrange M, Willems G (ed): State of the art on direct posterior filling materials and dentine bonding. Leuven, Van der Poorten, 1993, pp 15-28.

79-Elderton RJ, Mjör IA: Changing scene in cariology and operative dentistry. Int Dent J 1992;42:165-169.

Caries removal

The complete removal of demineralized and infected tissue is the aim of our therapy and is therefore a critical step ⁸⁰.

The softened dentin can be excavated with both low / very low speed burs or with hand instruments ^{80,83}.

In case of very deep caries, is more prudent to excavate the last layers with hand instruments, thus increasing the control and allowing to limit the risks of accidental pulp exposure ⁸². Dentin should be excavated until a hard and compact tissue is met ⁸². The color is not a diagnostic criterion ^{80,81,82}.

80-Yip HK, Samaranayake LP: Caries removal techniques and instrumentation: a review. Clin Oral Investig 1998 Dec;2(4):148-54. .

81-Kidd EAM, Ricketts DNJ, Beighton D: Criteria for caries removal at the enamel-dentine junction: a clinical and microbiological study. Br dent J 1996;180:287-291.

82-Weerheijm KL, Groen HJ: The residual caries dilemma. Community Dent Oral Epidemiol 1999 Dec;27(6):436-41.

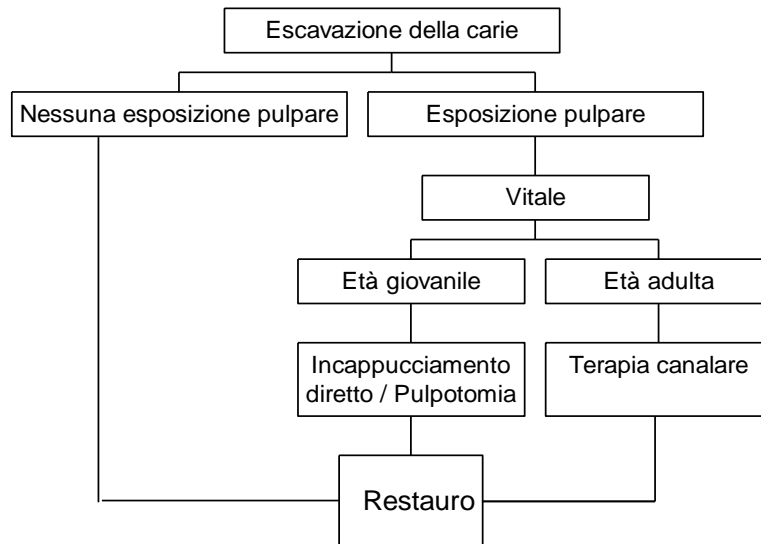
83-Smales RJ, Fang DT: In vitro effectiveness of hand excavation of caries with the ART technique. Atraumatic restorative treatment. Caries Res 1999 Nov-Dec;33(6):437-40.

Pulp protection

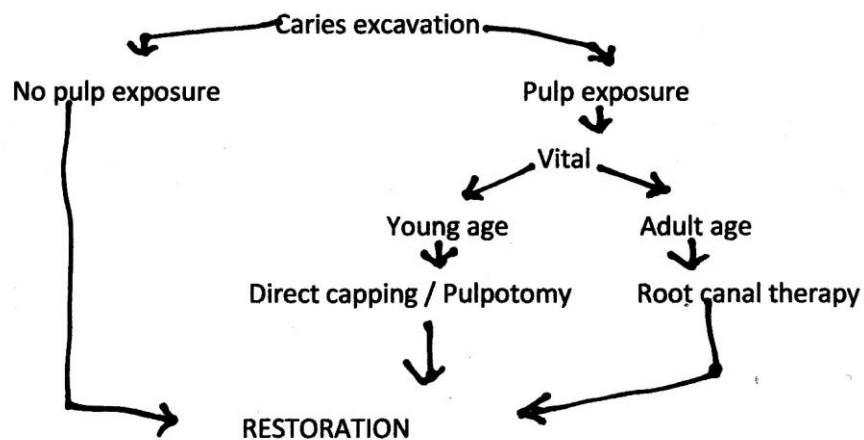
As a general rule the pulp should be adequately protected ^{84,85,86,87,88,89,90,91}.

The methods and materials to be used are at the discretion of the individual operator ^{92,93,94}.

***Percorso decisionale consigliabile
nel trattamento della carie profonda***



Decision-making process advisable in deep caries treatment.



- 84-Brannstrom M: A new approach to insulation. Dent Pract Dent Rec 1969 Aug;19(12):417-20.
- 85-Brannstrom M, Nyborg H: Pulp reaction to fluoride solution applied to deep cavities: an experimental histological study. J Dent Res 1971 Nov-Dec;50(6):1548-52.
- 86-Brannstrom M, Nyborg H: Cavity treatment with a microbicidal fluoride solution: growth of bacteria and effect on the pulp. J Prosthet Dent 1973 Sep;30(3):303-10.
- 87-Brannstrom M, Nyborg H : 65 Bacterial growth and pulpal changes under inlays cemented with zinc phosphate cement and Epoxylite CBA 9080. J Prosthet Dent 1974 May;31(5):556-511.
- 88-Brannstrom M, Vojinovic O: Response of the dental pulp to invasion of bacteria around three filling materials. J Dent Child 1976 Mar-Apr;43(2):83-9.
- 89-Brannstrom M, Nyborg H J: Pulp reaction to a temporary zinc oxide/eugenol cement. Prosthet Dent 1976 Feb;35(2):185-91.
- 90-Brannstrom M, Isacson G, Johnson G: The effect of calcium hydroxide and fluorides on human dentine. Acta Odontol Scand 1976;34(2):59-67.
- 91-Garberoglio R: La protezione della polpa. Attual Dent 1985 Dec 1;1(31):28-9.
- 92-Strassler HE: New concepts with bases and liners. J Esthet Dent 1992 Jul-Aug;4(4):140-1. II
- 93-LeinfelderKF: Changing restorative traditions: the use of bases and liners. J Am Dent Assoc 1994;125:65-67.
- 94-Leinfelder KF: An alternative approach to bonding and pulpal protection. Dent Today 1997 Apr;16(4):88-9. I

Recommendations

- *The preparation of the cavity must be the most conservative possible, consistent with the extension of the carious process and with the material and the technique (direct or indirect) chosen by the operator; **Lev.II***
- *The correct finishing of the margins is recommended to improve the marginal adaptation and longevity of the restoration; **Lev.I***
- *A proper isolation of the operating field is essential for therapeutic success; **Lev.II***
- *The removal of caries is a fundamental step of the conservative therapy. All the softened tissue must be removed up to reaching clinically healthy dentin, before the final restoration. The color of dentin is not a clinical indication; **Liev.II***
- *The pulp should be adequately isolated and protected.*

Insertion of the material

Depending on the clinical condition and the preferences of the individual operator the materials and techniques available are used ^{95,96}.

Generally speaking, it is essential to carefully follow the instructions and the modalities for use established by the individual manufacturers (application times, mixing ratios etc.) ^{97,98,99,100,101}.

95-Anusavice KJ: Criteria for selection of restorative materials: properties versus technique sensitivity, in Anusavice KJ (ed): Quality Evaluation of Dental Restorations: Criteria for Placement and Replacement. Chicago, Quintessence Publ Co, 1989, pp15-59.

96-Krejci I: Standortbestimmung in der Konservierenden Zahnmedizin. Schweiz Monatsschr Zahnmed 1993;103:614-619.

97-Unterbrink GL, Muessner R: Influence of light intensity on two restorative systems.

Journal of Dentistry 1995;23:183-189.

98-Watts C: Kinetic mechanisms of visible-light-cured resins and resin-composites.

Setting mechanisms of dental materials pp 80-112 Transactions of the Academy of Dental Materials, 1992.

99-Swift EJ, Perdigao J, Heymann HO: Bonding to enamel and dentin: a brief history and state of the art, 1995 Quintessence International 1995;26:95-110.

100-Kildal KK, Ruyter IE: How different curing methods affect mechanical properties of composites for inlays when tested in dry and wet conditions. Eur J Oral Sci 1997 Aug;105(4):353-61.

101Ferrari M, Kugel G: Handling characteristics of resin composites in posterior teeth. Compend Contin Educ Dent 1998 Sep;19(9):879-82.

Material selection.

In the frontal areas, composite resins in combination with a suitable adhesive system are the material of choice for direct restoration procedures^{102,103,104,105,106,107,108}.

In the posterior region, silver amalgam still represents a reliable and safe material^{109,110,111,112,113,114,115,116}. The Italian Ministry of Health has, however, recently recommended to avoid its use in pregnant women and in children.

Even composite resins, combined with the use of dentin adhesives have shown good results on premolars and molars^{117,118,119,120,121,122}. Their proper placement, however, requires more attention and a more complex operating technique, compared to the use of silver amalgam^{123,124,125,126}.

Other materials and cements for dental use (compomers, glass ionomers self - or photo-polymerizable, cermets) because of their non-optimal physico-chemical properties should not be used for permanent restorations subjected to occlusal loads^{127,128,129,130,131,132,133,134}.

Cast gold restorations continue to represent probably the most reliable and long lasting therapeutic choice^{135,136,137,138,139,140,141,142}.

Besides these, the aesthetic ceramic and composite resin inlays cemented with adhesive technique are increasingly demonstrating their clinical validity^{143,144,145,146,147,148,149,150,151}.

The dentin adhesives are an excellent means of anchoring the materials to the tooth^{152,153,154,155,156,157,158,159,160,161,162,163}. The action of various chemicals that modify dentin and enamel to promote their adhesion to composite resin is strongly disturbed by external pollutants (blood, saliva, etc.)^{164,165,166}. A proper isolation of the operating field is essential^{167,168}.

102-Degrang M: Coronal filling biomaterials. Criteria for selection. Real Clin 1990;1:9-26.

- 103-Qvist V. & Strom C.: 11-Year assessment of class-III resin restorations completed with two restorative procedures. *Acta Odontologica Scandinavica* 1993;51:253-262.
- 104-Portalier L :Composite smile designs: the key to dental artistry. *Curr Opin Cosmet Dent* 1997;4:81-85.
- 105-Lacy AM: Application of composite resin for single-appointment anterior and posterior diastema closure. *Pract Periodontics Aesthet Dent* 1998;10:279-286.
- 106-Peumans M, Van Meerbeek B, Lambrechts P, Vanherle G: The 5-year clinical performance of direct composite additions to correct tooth form and position. II. Marginal qualities. *Clin Oral Investig* 1997;1:19-26.
- 107-Jokstad A, Mjor IA, Nilner K, Kaping S: Clinical performance of three anterior restorative materials over 10 years. *Quintessence Int* 1994;25:101-108.
- 108-Kreulen CM, Creugers NH, Meijering AC: Meta-analysis of anterior veneer restorations in clinical studies. *J Dent* 1998;26:345-53.
- 109-Smales RJ, Hawthorne WS: Long-term survival and cost-effectiveness of five dental restorative materials used in various classes of cavity preparations. *Int Dent J* 1996;46:126-30.
- 110-Mair LH: Ten-year clinical assessment of three posterior resin composites and two amalgams. *Quintessence Int* 1998;29:483-490.
- 111-Roulet JF. Longevity of glass ceramic inlays and amalgam-results up to 6 years. *Clin Oral Investig* 1997;8:40-46.
- 112-van der Merwe WJ: Clinical evaluation of four dental amalgams over a three year period *J Dent Assoc S Afr* 1993;48:329-332.
- 113-Plasmans PJ, Creugers NH, Mulder J: Long-term survival of extensive amalgam restorations. *J Dent Res* 1998;77:453-60
- 114-Martin JA, Bader JD Five-year treatment outcomes for teeth with large amalgams and crowns. *Oper Dent* 1997;22:72-8.
- 115-Stratis S, Bryant RW: The influence of modified cavity design and finishing techniques on the clinical performance of amalgam restorations: a 2-year clinical study. *J Oral Rehabil* 1998 Apr;25:269-278.
- 116-Qvist V, Laurberg L, Poulsen A, Teglers PT: Longevity and cariostatic effects of everyday conventional glass-ionomer and amalgam restorations in primary teeth: three-year results. *J Dent Res* 1997;76:1387-96.
- 117-Raskin A, Michotte-Theall B, Vreven J, Wilson NH: Clinical evaluation of a posterior composite 10-year report. *J Dent* 1999;27:13-9.

- 118-Scheibenbogen-Fuchsbrunner A, Manhart J, Kremers L, Kunzelmann KH,
- 119-Hickel R: Two-year clinical evaluation of direct and indirect composite restorations in posterior teeth. *J Prosthet Dent* 1999;82:391-7.
- 120-Wendt SL Jr, Ziemiecki TL, Leinfelder KF: Proximal wear rates by tooth position of resin composite restorations. *J Dent* 1996;24:33-9
- 121-Wassell RW, Walls AW, McCabe JF: Direct composite inlays versus conventional composite restorations: three-year clinical results. *Br Dent J* 1995;179:343-349.
- 122-Collins CJ, Bryant RW, Hodge KL: A clinical evaluation of posterior composite resin restorations: 8-year findings. *J Dent* 1998;26:311-317.
- 123-Tobi H, Kreulen CM, Gruythuysen RJ, van Amerongen WE: The analysis of restoration survival data in split-mouth designs. *J Dent* 1998;26:293-298.
- 124-Hawthorne WS, Smales RJ: Factors influencing long-term restoration survival in three private dental practices in Adelaide. *Aust Dent J* 1997;42:59-63.
- 125-Liebenberg WH: Direct-indirect resin restoration: a case report of acceptable compromise. *J Can Dent Assoc* 1997;63:265-72.
- 126-Christensen GJ: Current use of tooth-colored inlays, onlays, and direct-placement resins. *J Esthet Dent* 1998;10:290-5.
- 127-Puckett A, Fitchie JG, Dellinger TM, Roberts B, Stinett B: The effect of delayed photocuring on the hardness of resin-modified glass ionomers. *Miss Dent Assoc J* 1999;5:36-39.
- 128-Best JM: The use of glass ionomers in pediatric patients. *Dent Today* 1998;17:82-85.
- 129-Marks LA, van Amerongen WE, Borgmeijer PJ, Groen HJ, Martens LC: Ketac molar versus dyract class II restorations in primary molars: twelve month clinical results. *J Dent Child* 2000;67:37-41.
- 130-McLean A J: Glass ionomer restorations. *Can Dent Assoc* 2000;66:11-14.
- 131-Croll TP, Killian CM: Class I and class II light-hardened glass-ionomer/resin restorations. *Compendium* 1993;14:908, 910-912.
- 132-Wilson NH, Cowan AJ, Crisp RJ, Wilson MA: A short-term clinical evaluation of a tricure glass-ionomer system as a transitional restoration and core buildup material. *Quintessence Int* 1999;30:405-411.
- 133-Burke FJ, Cheung SW, Mjor IA, Wilson NH: Restoration longevity and analysis of reasons for the placement and replacement of restorations provided by vocational dental practitioners and their trainers in the United Kingdom. *Quintessence Int* 1999;30:234-242.

- 134-Mjor IA, Moorhead JE, Dahl JE: Selection of restorative materials in permanent teeth in general dental practice. *Acta Odontol Scand* 1999;57:257-262.
- 135-Nordbo H, Lyngstadaas SP: The clinical performance of two groups of functioning class-II cast gold inlays. *Acta Odontol Scand* 1992;50:189-192.
- 136-Newman SM: Amalgam alternatives: what can compete? *J Am Dent Assoc* 1991;122:67-71.
- 137-Mjor IA, Jokstad A, Qvist V: Longevity of posterior restorations. *Int Dent J* 1990;40:11-27.
- 138-Davis SH Excellence in dentistry: posterior rehabilitation using cast gold onlays. *Dent Manage* 1988;28:38-43.
- 139-Liberman R, Judes H, Cohen E, Eli I: Restoration of posterior pulpless teeth: amalgam overlay versus cast gold onlay restoration. *J Prosthet Dent* 1987;57:540-543.
- 140-Donovan TE, Cho GC: Materials for conservative posterior restorations. *J Calif Dent Assoc* 1996 Sep;24(9):32-38.
- 141-Christensen GJ: The coming demise of the cast gold restoration? *J Am Dent Assoc* 1996;127:1233-1236.
- 142-Tucker RV: Gold restorations of the distal aspect of cuspid teeth. *Signature* 1996; Winter:4-9.
- 143-Abel MG: In-office inlays with today's new materials. *Dent Clin North Am* 1998;42:657-64.
- 144-McLaren EA, Rifkin R, Devaud V: Considerations in the use of polymer and fiber-based indirect restorative materials. *Pract Periodontics Aesthet Dent* 1999;11:423-32.
- 145-Chalifoux PR: Treatment considerations for posterior laboratory-fabricated composite resin restorations. *Pract Periodontics Aesthet Dent* 1998;10:969-78.
- 146-Shannon A: Indirect posterior restorations: steps to clinical success. *Curr Opin Cosmet Dent* 1997;4:40-4.
- 147-Koczarski MJ: Utilization of ceromer inlays/onlays for replacement of amalgam restorations. *Pract Periodontics Aesthet Dent* 1998;10:405-12.
- 148-Behle CA: Conservative direct and indirect resin posterior restorative alternatives for cracked dentition. *Pract Periodontics Aesthet Dent* 1997;9:405-13.
- 149-Rees JS, Jacobsen PH: The restoration of posterior teeth with composite resin. 2: Indirect-placement composite. *Dent Update* 1997;24:25-30.
- 150-Shannon AJ: Clinical guidelines for indirect resin restorations. *Can Dent Assoc* 1997;63(6):432-7.

- 151-Liberman R, Ben-Amar A, Herteanu L, Judes H: Marginal seal of composite inlays using different polymerization techniques. *J Oral Rehabil* 1997;24:26-9.
- 152-Swift EJ Jr: Bonding systems for restorative materials-a comprehensive review. *Pediatr Dent* 1998;20:80-84.
- 153-Pashley DH, Carvalho RM: Dentine permeability and dentine adhesion. *J Dent* 1997;25:355-372.
- 154-Eick JD, Gwinnett AJ, Pashley DH, Robinson SJ: Current concepts on adhesion to dentin. *Crit Rev Oral Biol Med* 1997;8:306-335.
- 155-Prati C: In vitro and in vivo adhesion in operative dentistry: a review and evaluation. *Pract Periodontics Aesthet Dent* 1998;10:319-327.
- 157-Charlton DG Dentin bonding: past and present. *Gen Dent* 1996;44:498-507.
- 158-Kanca J 3rd: One step bond strength to enamel and dentin. *Am J Dent* 1997;10:5-8.
- 159-Leinfelder KF: Current status of dentin adhesive systems. *Alpha Omegan* 1998;9:17-22.
- 160-Freedman G, Goldstep F: Fifth generation bonding systems: state of the art in adhesive dentistry. *J Can Dent Assoc* 1997 Jun;63(6):439-43
- 161-Van Meerbeek B, Vanherle G, Lambrechts P, Braem M: Dentin- and enamel-bonding agents. *Curr Opin Dent* 1992;2:117-127.
- 162-Dietschi D, De Siebenthal G, Neveu-Rosenstand L, Holz J: Influence of the restorative technique and new adhesives on the dentin marginal seal and adaptation of resin composite Class II restorations: an in vitro evaluation. *Quintessence Int* 1995;26:717-727.
- 163-Frankenberger R, Sindel J, Kramer N, Petschelt A: Dentin bond strength and marginal adaptation: direct composite resins vs ceramic inlays. *Oper Dent* 1999;24:147-55.
- 164-Hitmi L, Attal JP, Degrange M: Influence of the time-point of salivary contamination on dentin shear bond strength of 3 dentin adhesive systems. *J Adhes Dent* 1999;1(3):219-32.
- 165-Strassler HE: Isolation of the field more important than ever. *MSDA J* 1996 Fall;39(3):119-21.
- 166-Lygidakis NA, Oulis KI, Christodoulidis A: Evaluation of fissure sealants retention following four different isolation and surface preparation techniques: four years clinical trial. *J Clin Pediatr Dent* 1994 Fall;19(1):23-5.
- 167-Smales RJ: Effect of rubber dam isolation on restoration deterioration. *Am J Dent* 1992;5:277-279.

168-Smales RJ, Webster DA: Restoration deterioration related to later failure. Operative Dentistry 1993;18:130-137.

Pre-prosthetic reconstruction of endodontically treated teeth.

The preprosthetic restoration can be performed with silver amalgam or composite resin anchored to a root canal post, or with a prefabricated castgold post and core, or by using a resin and carbon fibers post cemented with resin cement or tself-curing composite resin cement¹⁶⁹. The latter method allows probably better preservation of dentin and a chemical-mechanical bond to dentin ^{169,170}.

The pin should not be considered as a reinforcement of the tooth , but only a support for the reconstruction material ¹⁷¹.

The use of a post is required when the height of the pulp chamber is poor (in molars) or when less than three remaining walls are present at the coronal level (premolars and front teeth)^{172,175}.

The subsequent prosthetic preparation should follow the principle of conservation of dentin at the cervical level: it seems that an area of embrace of coronal dentin (ferrule effect) significantly increases the chances of survival of the endodontically treated teeth^{173,174}.

In cases where it is not possible to perform a cervical ferrule effect of about 1.5-2 mm, it is probably advisable to resort to a crown lengthening periodontal surgical procedure ^{1173,174}.

169-Assif D, Oren E, Marshk BL: Photoelastic analysis of stress transfer in endodontically treated teeth to the supporting structure using different restorative tecnique. J Prosthet Dent 1989; 61: 535-543.

170-Sornkul E, Strength of root before and after endodontic treatement and restoration. J Endod 1992; 18,9: 440-44

171-Mentink A.G.B.,Creugers N: Five year report of a clinical trial on post and core restorations. JADR 1995, 74: 187-92.

172-Randow K, Glantz P.O: On cantilever loading of vital and non vital teeth. An experimental clinical study. Acta Odontol Scand 1986; 44:271.

173-Sorensen JA, Engelman MJ: Ferrule design and fracture resistance of endodontically treated teeth. J Prosthet Dent 1990; 63 :529-536.

174-Hansen EK, Asmussen E, Christiansen NC: In vivo fractures of endodontically treated posterior teeth restored with amalgam. Endod Dent Traum 1990; 6: 49-55.

175-Helfer AR, Melnik S, Schilder H: Determination of the moisture content of vital and pulpless teeth. Oral Surg 1972; 34: 661-9.

Finishing and polishing.

All restorations must be finished and polished ¹⁷⁶.

Finishing and polishing are performed with instruments and burs with decreasing cutting action ^{176,177,178}.

A smooth and polished surface is less retentive for bacterial plaque and contributes to obtaining a good marginal adaptation ^{179,180,181,182}.

176-Lutz F, Setcos JC, Phillips RW: New finishing instruments for composite resins JADA 1983;107:575-580.

177-Krejci I, Lutz F: Kompositfüllungen - das 1X1 des Ausarbeiten. Schweiz Monatsschr Zahnmed 1984;94:1015-1028.

178-Herrgott A N, Ziemiecki T L, Dennison J B: An evaluation of different composite resin systems finished with various abrasives. JADA 1989;119:729-732.

179-Hondrum SO, Fernandèz R: Contouring, finishing and polishing class 5 restorative materials. Oper Dent 1997;22:30-36.

180-Schmid O, Krejci I, Lutz F: Ausarbeitung von adhäsiven zahnfarbenen Inlays aus Komposit und Keramik. Schweiz Monatsschr Zahnmed 1991;101:177-184.

181-O'Brien W J, Johnston W M, Fanian F, Lambert S: The surface roughness and gloss of composites. J Dent Res 1984;63:685-688.

182-Briand DE: Les composite d'obturation - étude expérimentale de la finition des surfaces par abrasion. Actualités Odonto-Stomatologiques 1990;172:619-649.

Maintenance therapy

The patient should be advised to follow a maintenance program that includes control visits, sessions of oral hygiene and possible topical application of fluorides ^{183,184,185}. La presenza incontrollata di placca batterica ovviamente aumenta il rischio di carie secondaria per qualunque restauro ¹⁸⁶.

183-Axelsson P, Lindhe J: Effect of controlled oral hygiene procedures on caries and periodontal disease in adults. J Clin Period: 1978;5:133-151.

184-Axelsson P, Lindhe J: Effect of controlled oral hygiene procedures on caries and periodontal disease in adults. Results after 6 years. J Clin Period: 1981; 8:239-248.

185-Axelsson P, Lindhe J, Nyström M: On the prevention of caries and periodontal disease. Results of a 15-year longitudinal study in adults. J. Clin. Period: 1991;18:182-189.

186-Marthaler T M: Zahnkaries und Zahnverlust bis zum Jahre 2008: Prognosen für die 25- bis 65jährigen Erwachsenen. Schweiz Monatsschr Zahnmed 1993;103:1476-1477.

Recommendations

- *The correct insertion and manipulation of materials is a critical point in the execution of any restoration; **Lev.II***
- *The restoration should not interfere with the dynamics of occlusion; **Lev.II***
- *The cervical margins should be contoured so as not to irritate the periodontal tissues; **Lev.II***
- *A restoration with smooth, polished surface is less retentive for bacterial plaque. This reduces the risk of recurrent caries and marginal tissue inflammation; **Lev.II***
- *A periodic inspection and possible re-polishing of restorations can probably contribute to their increased duration. **Lev.I***